

# Morphometry of Lumbar Spine- A Holistic Comparative Study between Typical and Atypical Lumbar Vertebrae

GYANARANJAN NAYAK<sup>1</sup>, SITANSU KUMAR PANDA<sup>2</sup>, PRAFULLA KUMAR CHINARA<sup>3</sup>

## ABSTRACT

**Introduction:** Morphometry of body and neural arch of lumbar vertebrae is very crucial in manufacturing screws, interspinous implants as well as preoperative planning of surgeries involving dorsolumbar spine.

**Aim:** To determine various dimensions of typical and atypical lumbar vertebrae.

**Materials and Methods:** A descriptive osteological study was carried out which included 66 intact adult dry human lumbar vertebrae (53 typical and 13 atypical) which were free of any deformity or pathological features. All the 53 typical vertebrae were randomly obtained. The following parameters were measured with slide callipers- superior transverse diameter and superior antero-posterior diameters of vertebral foramen; transverse diameter, antero-posterior diameter and anterior height of vertebral body; width, height of pedicles; interpedicular distance; maximum thickness of lamina; length of transverse process; maximum length, maximum height and maximum central thickness of spinous process. The data was tabulated and analysed using Microsoft Excel software. Mean and standard deviation was calculated for each parameter. Unpaired t-test was applied and p-value was derived for parameters like width and height of pedicles, thickness of lamina and length of transverse process. The p-value<0.05 were considered as significant.

**Results:** The vertebral foramen (superior transverse diameter- 20.41±2.54 mm, superior antero-posterior diameter- 13.3±2.04 mm); vertebral body (transverse diameter- 44.43±5.91 mm, antero-posterior diameter- 30.17±3.19 mm, anterior height- 24.01±1.84 mm); pedicle (width- 10.85±3.94 mm on left side and 11.04±4.01 mm on right side, height- 13.84±4.01 mm on left side and 13.8±1.93 mm on right side, interpedicular distance- 29.17±5.06 mm); lamina (thickness- 6.6±1.36 mm on left side and 6.85±1.34 mm on right side); transverse process (length- 20.94±4.01 mm on left side and 21.51±4.5 mm on right side); spinous process (maximum length- 26.01±3.73 mm, maximum height- 19.92±4.03 mm, maximum central thickness- 6.42±1.41 mm). The mean transverse diameter and antero-posterior diameter of vertebral foramen of atypical lumbar vertebrae were higher than those of the typical lumbar vertebrae and these differences were significant (p-value of 0.0001 for transverse diameter and p-value of 0.005 for antero-posterior diameter).

**Conclusion:** Most of the parameters of atypical lumbar vertebrae were found to be more compared to those of typical lumbar vertebrae. This inference should be kept in mind during fixation of lumbar inter-spinous implants, designing of pedicular screws and spinal grafting.

**Keywords:** Dimensions, Lumbar vertebral column, Neural arch, Vertebral body

## INTRODUCTION

Dimensions of lumbar vertebrae are of utmost importance in diagnosing lower back pain and lumbar spinal stenosis. In lumbar spinal stenosis, there's reduction of antero-posterior and lateral dimensions of the lumbar vertebral canal resulting in low backache [1]. Developmental lumbar spinal canal stenosis can be due to anomalous neural arch, pedicles, laminae and articular processes resulting from shortening of lateral sagittal diameters of spinal canal due to thickened laminae and articular processes of lumbar vertebrae [2]. Another cause of low back pain is lumbar degenerative disc disease which results from deteriorated lumbar intervertebral discs. Late phase lumbar degenerative disc disease is treated by interspinous process implant which is a minimally invasive novel surgical procedure [3]. This surgical procedure has many advantages, but complications such as implant device migration and spinal fracture may occur [4]. So, thorough knowledge of dimensions of lumbar spinous processes is important for proper interspinous process implantation to prevent post-operative complications [5].

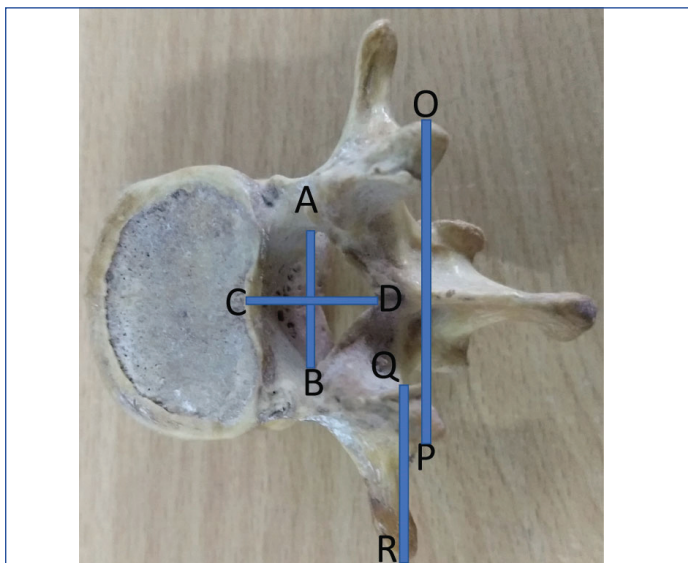
Pedicles of lumbar vertebrae are frequently utilised as sites of fixation for lumbar spinous implants [6]. The pedicles of lumbar vertebrae are used to gain access for injecting acrylic cement into the body of fractured vertebrae for their stabilisation,

restoring vertebral height and reducing spinal deformity [7]. Various devices such as rods, plates or wires are fixed to the vertebral column by screws for immobilisation [8]. Transpedicular screw implantation techniques have become popular in recent years [9]. The pedicles provide an excellent implantation site for screw fixation in reconstructive spine surgeries imparting proper stability. However, misplaced and misdirected pedicle screw may injure pedicle cortex, nerve root, zygapophyseal joints and other vital structures [10]. It's imperative to have knowledge of pedicle dimensions for safe placement of pedicle screws. The pedicle screw is inserted through posterior surface of the pedicle into the vertebral body. The selection of the screw to be used is determined by the dimensions of the pedicle. So, pedicular morphometry is of immense help in preoperative planning as well as designing pedicle screws and other implantable devices [11]. The dimensions of transverse processes along with those of the pedicles of vertebrae, determine the better acceptance of spinal grafts during spinal surgery [12]. Thus, the morphometry of lumbar vertebrae is of paramount importance in spine surgery and diagnosing low back pain. Therefore, an attempt was made to perform the morphometric analysis of the body and neural arch of lumbar vertebrae in a single study as only few such holistic studies [1,12] involving both the body and neural arch of lumbar vertebrae together have been performed till date.

## MATERIALS AND METHODS

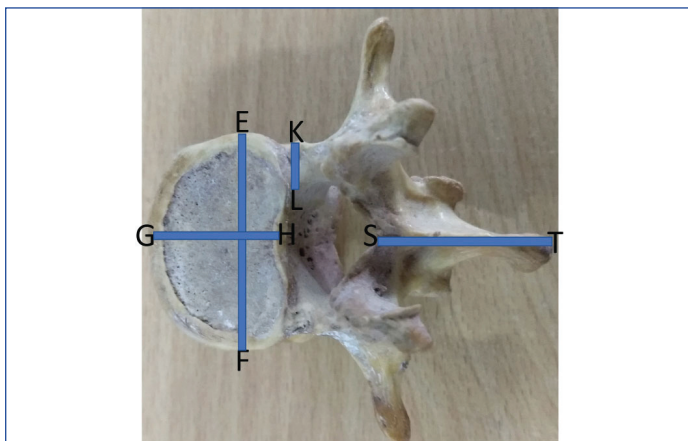
A descriptive osteological study was conducted which included 66 dry lumbar vertebrae (53 typical and 13 atypical). The vertebrae were procured from the departmental museum of Anatomy of a Medical College of Eastern India. All the vertebrae belonged to adult males as per the record of the museum. The vertebrae were segregated into two groups: typical and atypical. Broken and deformed vertebrae with obvious pathological derangements were excluded from the study. The vertebrae were measured with slide callipers and recording was observed in mm with a precision reading from 0.01 mm. The following parameters were measured [1,12].

- A. Superior transverse and superior antero-posterior diameters of vertebral foramen [Table/Fig-1]- Superior transverse diameter of vertebral foramen (AB) was taken as the maximum transverse distance across superior aspect of vertebral foramen. Superior antero-posterior diameter of vertebral foramen (CD) was taken as the maximum antero-posterior distance across superior aspect of vertebral foramen.

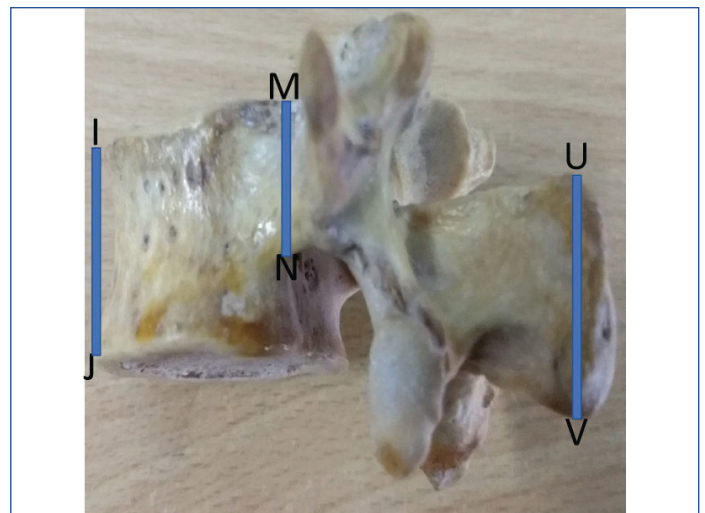


**[Table/Fig-1]:** Lumbar vertebra showing superior transverse diameter of vertebral foramen-AB, superior antero-posterior diameter of vertebral foramen-CD, interpedicular distance-OP, length of transverse process-QR.

- B. Transverse diameter [Table/Fig-2], antero-posterior diameter [Table/Fig-2] and anterior height [Table/Fig-3] of the vertebral body-Transverse diameter of body (EF) were taken as the maximum transverse distance across the superior surface of vertebral body. Antero-posterior diameter of body (GH) was taken as the maximum antero-posterior distance across the superior surface of vertebral body. Anterior height of vertebral body (IJ) was taken as the maximum vertical measurement across anterior surface of vertebral body.



**[Table/Fig-2]:** Lumbar vertebra showing transverse diameter of the body- EF, antero-posterior diameter of the body- GH, maximum width of pedicle- KL, maximum length of spinous process-ST.



**[Table/Fig-3]:** Lumbar vertebra showing anterior height of vertebral body- IJ, height of pedicle- MN, maximum height of spinous process- UV.

- C. Width [Table/Fig-2] and height [Table/Fig-3] of the pedicles as well as interpeduncular distance [Table/Fig-1]-Width of pedicle (KL) was taken as the maximum transverse measurement on the superior surface of vertebral pedicle. Height of the pedicle (MN) was taken as the maximum vertical measurement of pedicle i.e., from the highest point of superior surface of pedicle to the lowest point on the inferior surface of pedicle. Interpedicular distance (OP) was taken as the transverse distance across the upper ends of the two superior articular processes of vertebra.
- D. Thickness of the lamina- It was taken as the maximum measurable thickness of the lamina.
- E. Length of the transverse process (QR in [Table/Fig-1]): It was measured as the distance across lateral extreme of superior aspect of vertebral foramen and tip of transverse process.
- F. Maximum length [Table/Fig-2], maximum height [Table/Fig-3] and maximum central thickness of the spinous process- Maximum length of the spinous process (ST) was measured as the distance between the most anterior point and most posterior point on the superior border of spinous process. Maximum height of spinous process (UV) was measured as the vertical distance between most posterior points on superior and inferior borders of spinous process. Maximum central thickness of spinous process was measured as the maximum transverse distance between the central points of lateral surfaces of spinous process.

All the measurements were repeated thrice by different observers to exclude interobserver variations.

## STATISTICAL ANALYSIS

The observations were tabulated and analysed using Microsoft Excel software. Mean and standard deviations were obtained for each of the parameters. Unpaired t-test was applied and p-value was calculated for parameters like width and height of pedicles, thickness of lamina and length of transverse process. Difference was considered to be statistically significant if p-value obtained was <0.05.

## RESULTS

The mean transverse diameter and antero-posterior diameter of vertebral foramen of atypical lumbar vertebrae were higher than those of the typical lumbar vertebrae [Table/Fig-4]. These differences were significant (p-value of 0.0001 for transverse diameter and p-value of 0.005 for antero-posterior diameter). The vertebral foramen of atypical lumbar vertebrae was strictly of triangular shape while in typical lumbar vertebrae, it was triangular

with slightly round to oval contour. The vertebral foramina of atypical lumbar vertebrae were larger compared to that of typical lumbar vertebrae. The atypical lumbar vertebrae were found to possess more massive bodies than typical lumbar vertebrae. The mean transverse diameter, antero-posterior diameter and anterior height of vertebral body were higher for atypical lumbar vertebrae compared to typical lumbar vertebrae [Table/Fig-5]. However, the values were not statistically significant. The atypical lumbar vertebrae presented wider pedicles than typical lumbar vertebrae. However, the typical lumbar vertebrae were found to have more mean height of pedicle than the atypical ones. The mean pedicular width of atypical and typical lumbar vertebrae was more on the right side compared to left. The difference was not found to be statistically significant. However, the height of the pedicle was found to be higher on the left side in atypical lumbar vertebrae than right, the difference not being statistically significant. In typical lumbar vertebrae, the height of pedicle was more on the right side. The difference was not found to be statistically significant either [Table/Fig-6]. The mean thickness of the lamina of typical lumbar vertebrae was higher than that of atypical lumbar vertebrae on left side [Table/Fig-7]. The mean length of transverse process was higher for atypical lumbar vertebrae on both right and left sides compared to typical lumbar vertebrae [Table/Fig-8]. The spinous processes of typical lumbar vertebrae possessed more mean length and height than atypical lumbar vertebrae [Table/Fig-9].

Type of lumbar vertebra	Superior transverse diameter of vertebral foramen (mm)	Superior antero-posterior diameter (mm)
Atypical (n=13)	23.4±3.1 (18.5-30.31)	14.86±1.96 (11.67-17.5)
Typical (n=53)	19.68±1.75 (16.56-25.01)	12.92±1.89 (9.86-19.48)
Both typical and atypical (n=66)	20.41±2.54	13.3±2.04

[Table/Fig-4]: Dimensions of vertebral foramen of lumbar vertebrae.

Type of lumbar vertebra	Transverse diameter of vertebral body (mm)	Antero-posterior diameter of vertebral body (mm)	Anterior height of vertebral body (mm)
Atypical (n=13)	49.39±5.57 (40.56-60.61)	31.47±3.36 (24.39-37.57)	24±2.05 (20.88-27.05)
Typical (n=53)	43.21±5.37 (33.34-54.85)	29.85±3.09 (23.68-35.56)	23.98 ±1.83 (19.59-23.04)
Both typical and atypical (n=66)	44.43 ± 5.91	30.17±3.19	24.01±1.84

[Table/Fig-5]: Dimensions of vertebral body. Parenthesis shows the range in mm

Type of lumbar vertebra	Width of pedicle on left side of vertebra (mm)	Width of pedicle on right side of vertebra (mm)	p-value	Height of pedicle on left side of vertebra (mm)	Height of pedicle on right side of vertebra (mm)	p-value	Interpedicular distance (mm)
Atypical (n=13)	15.31±3.62 (10.68-22.26)	16.21±3.14 (11.89-24.51)	0.5	14.05± 2.98 (10.14-18.73)	12.38± 2.67 (8.97-16.93)	0.13	25.01±3.25 (21.36-30.47)
Typical (n=53)	9.76±3.19 (4.96-22.89)	9.77±3.08 (4.69-20.26)	0.9	13.79± 1.65 (10.29-20.23)	14.16± 1.52 (11.56-16.79)	0.24	35.28±4.92 (21.96-41.69)
Both typical and atypical (n=66)	10.85± 3.94	11.04±4.01	0.79	13.84± 4.01	13.8± 1.93	0.88	29.17±5.06

[Table/Fig-6]: Dimensions of vertebral pedicle. Parenthesis shows the range in mm; Unpaired t-test was applied

Type of lumbar vertebra	Thickness of lamina on left side of vertebra (mm)	Thickness of lamina on right side of vertebra (mm)	p-value
Atypical (n=13)	6.51±1.41 (5.01-10.6)	7.21±0.95 (5.64-7.97)	0.15
Typical (n=53)	6.62±1.36 (4.28-9.47)	6.77±1.41 (4.2-10.01)	0.58
Both typical and atypical (n=66)	6.6±1.36	6.85±1.34	0.27

[Table/Fig-7]: Dimensions of vertebral lamina. Unpaired t-test was applied; Parenthesis shows the range in mm

## DISCUSSION

The superior transverse diameter and superior antero-posterior diameter of vertebral foramen is 20.41±2.54 mm and 13.3±2.04 mm in the current study. Einstein [13] has reported a mean superior transverse diameter of 23 mm (average lower limit of normal 18 mm) and a mean superior antero-posterior diameter of 16 mm (lower limit of normal 13 mm) for vertebral foramen of lumbar vertebrae in his study, which was in agreement with the current study. The transverse diameter of vertebral body ranged from 40.56 mm to 60.61 mm in atypical lumbar vertebrae and from 33.34 mm to 54.85 mm in typical lumbar vertebrae. The antero-posterior diameter of vertebral body ranged from 24.39 mm to 37.57 mm in the typical lumbar vertebrae and from 23.68 mm to 35.56 mm in the typical lumbar vertebrae. Azu A et al., have reported antero-posterior diameter of body ranging between 23 mm-32.7 mm (L1, female); 27.8 mm-42 mm (L1, male); 26.7 mm-37.7 mm (L2, female); 25.5 mm-46 mm (L2, male); 23.9 mm-40.2 mm (L3, female); 27.7 mm-42.3 mm (L3, male); 27 mm-42.4 mm (L4, female); 27.4 mm-43 mm (L4, male); 31.5 mm-46.6 mm (L5, female); 31.9 mm-37.8 mm (L5, male) [1].

In the current study, pedicular width was found to be 15.31±3.62 mm (left side) and 16.21±3.14 mm (right side) for atypical lumbar vertebrae. Pedicular width was 9.76±3.19 mm (left side) and 9.77±3.08 mm (right side) for typical lumbar vertebrae. Pedicular height was derived to be 14.05±2.98 mm (left side) and 12.38±2.67 mm (right side) for atypical lumbar vertebrae. Typical lumbar vertebrae presented a pedicular height of 13.79±1.65 mm on left side and 14.16±1.52 mm on the right side. Various authors have reported similar values. Singel TC et al., have reported average width at the mid-point of pedicle to be 9.52 mm in dry bones [14]. Other average values reported for typical lumbar vertebrae are 7.18 mm on left side and 6.98 mm on right side by Tan SH et al., [15]; 8.68 mm on left side and 8.68 mm on right side by Lien SB et al., [16]. Patil BK and Bhuyan PS have reported the average width of pedicle of typical lumbar vertebrae at the midpoint of pedicle as 8.57±1.69 mm on the left side and 8.41±1.62 mm on right side. They have reported the average height of pedicle of typical lumbar vertebrae at the midpoint of pedicle as 13.9±1.39 mm on the right side [17]. Chandni G et al., have reported pedicular width as 7±2 mm on right side and 8±2 mm on left side for typical lumbar vertebrae; 14±2 mm on right side and 14±2 mm on left side for atypical lumbar vertebrae. They have reported pedicular height as 13±1 mm on right side and 12±1 mm on left side for atypical lumbar vertebrae [18]. Marasini RP et al., have reported average horizontal diameter of pedicle as 7.17 mm for first lumbar vertebra, 7.62 mm for second lumbar vertebra, 9.5 mm for third lumbar vertebra, 10.51 mm for fourth lumbar vertebra, 11.3

Type of lumbar vertebra	Length of transverse process on left side of vertebra (mm)	Length of transverse process on right side of vertebra (mm)	p-value
Atypical (n=13)	21.05±3.15 (17.79-25.85)	21.8±3.1 (16-27.86)	0.54
Typical (n=53)	20.92±4.22 (13.22-34.64)	21.44±4.8 (11.93-28.61)	0.55
Both typical and atypical (n=66)	20.94±4.01	21.51±4.5	0.44

[Table/Fig-8]: Dimensions of vertebral transverse process. (Unpaired t test was applied; Parenthesis shows the range in mm)

Type of lumbar vertebra	Maximum length of spinous process (mm)	Maximum height of spinous process (mm)	Maximum central thickness of spinous process (mm)
Atypical (n=13)	23.83±3.12 (19.59-31.86)	15.93±3.26 (11.73-24.12)	6.8±1.55 (4.54-9.5)
Typical (n=53)	26.55±3.7 (17.52-34.32)	20.9±3.59 (10.72-27.85)	6.32±1.37 (4.12-13.01)
Both typical and atypical (n=66)	26.01±3.73	19.92±4.03	6.42±1.41

**[Table/Fig-9]:** Dimensions of vertebral spinous process. Parenthesis shows the range in mm

mm for fifth lumbar vertebra and average vertical diameter of pedicle as 15 mm for first lumbar vertebra, 15.28 mm for second lumbar vertebra, 15.21 mm for third lumbar vertebra, 13.44 mm for fourth lumbar vertebra, 12.59 mm for fifth lumbar vertebra [19].

The interpedicular distance was established as 25.01±3.25 mm for atypical lumbar vertebrae and 35.28±4.92 mm for typical lumbar vertebrae in the present study. Mean interpedicular distance was established as 25.54 mm (L1), 27.03 mm (L2), 27.7 mm (L3), 28.62 mm (L4), 31.39 mm (L5) by Marasini RP et al., [19] and Azu A et al., have also reported similar interpeduncular distance as in present study [1]. In the current study, the length of transverse process was found to be 21.05±3.15 mm on left side; 21.8±3.1 mm on right side for atypical lumbar vertebrae and 20.92±4.22 mm on left side, 21.44±4.8 mm on right side for typical lumbar vertebrae. Tyagi S and Narayan RK have reported similar length of transverse process as in present study [12]. The values of maximum length, maximum height and maximum central thickness of spinous process for both atypical and typical lumbar vertebrae resembles with the findings of Tyagi S and Narayan RK and Ran B et al., [12,20]. Ran B et al., have established the average height of spinous process as 8.9-33.5 mm (male) and 7.6-28.4 mm (female) for typical lumbar vertebrae; 10.1-31.5 mm (male) and 7.8-25.6 mm (female) for atypical lumbar vertebrae and the central thickness of spinous process was measured as 7.94±1.9 mm (male) and 6.18±1.16 mm (female) [20].

The current study provides a complete morphometry of lumbar vertebrae. The findings of the study will be highly relevant in orthopaedic surgery and radiological evaluation involving lumbar spine. Procedures such as lumbar spinal implantation, kyphoplasty and vertebroplasty of lumbar spine and lumbar laminectomy require detailed knowledge of the different dimensions of lumbar vertebrae.

### Limitation(s)

It is recommended that cadaveric and radiological evaluation of the different dimensions of body and neural arch of lumbar vertebrae may be carried out in Indian population, which will further add on the information. The present study, being a drybone study, has not described the possible age and sex related variations of lumbar spinous morphometry.

### CONCLUSION(S)

The lumbar spine is a frequent site for injuries, osteoporosis and degenerative disorders like lumbar spondylosis. Morphometric data of the current study is relevant in radiology and spine surgeries for selection of pedicle screw and interspinous implant for operative repair of such disorders. The cadaveric and radiological studies can describe the variations in morphometry of lumbar spine in relation

to age and sex which can enhance the knowledge rendered by the present study.

### REFERENCES

- [1] Azu OO, Komolafe OA, Ofusori DA, Ajayi SA, Naidu ECS, Abiodun AA. Morphometric study of lumbar vertebrae in adult South African subjects. *Int J Morphol.* 2016;34(4):1345-51.
- [2] Verbiest H. Results of surgical treatment of idiopathic developmental stenosis of lumbar vertebral canal-A review of twenty-seven years of experience. *J Bone Joint Surg Br.* 1977;59(2):181-88.
- [3] Oppenheimer JH, Decastro I, Mcdonell DE. Minimally invasive spine surgery- A historical review. *Neurosurg Focus.* 2009;27(3):E9.
- [4] Bowers C, Amini A, Dailey AT, Schimdt MH. Dynamic interspinous process stabilisation: Review of complications associated with the X-stop device. *Neurosurg Focus.* 2010;28(6):E8.
- [5] Ihm EH, Han IB, Shin DA, Kim TG, Hun R, Chung SS. Spinous process morphometry for interspinous device implantation in Korean patients. *World Neurosurg.* 2013;79(1):172-76.
- [6] Matsuzaki H, Tokuhashi Y, Matsumoto F, Hoshino M, Kiuchi T, Toriyama S. Problems and solutions of pedicle screw plate fixation of lumbar spine. *Spine (Phila PO-1976).* 1990;15(11):1159-65.
- [7] Lieberman I, Reinhardt MK. Vertebroplasty and kyphoplasty for osteolytic vertebral collapse. *Clin Orthop Relat Res.* 2003;415(Suppl):S176-86.
- [8] Amonoo-Koufi HS. Age related variations in the horizontal and vertical diameters of the pedicles of the lumbar spine. *J Anat.* 1995;186(2):321-38.
- [9] Zindrick MR, Wiltse LL, Widell EH, Thomas JC, Russell WH, Field BT, et al. A biomechanical study of inter-pedicular screw fixation in the lumbosacral spine. *Clin Orthop Rel Res.* 1986;203:99-112.
- [10] Meisenhimer GR, Peek RD, Wiltse LL, Rothman SL, Widell EH Jr. Anatomic analysis of pedicle cortical and cancellous diameter as related to screw size. *Spine.* 1989;14(4):367-72.
- [11] Chawla K, Sharma M, Abhaya A, Kochhar S. Morphometry of the lumbar pedicle in North West India. *Eur J Anat.* 2011;15(3):155-61.
- [12] Tyagi S, Narayan RK. Study of the morphometric variations of the neural arch in the lumbar vertebrae in adult human skeleton of North Indian population. *Int J Orth Sci.* 2018;4(1):806-09.
- [13] Einstein S. The morphometry and pathological anatomy of the lumbar spine in South African Negroes and Caucasoids with specific reference to spinal stenosis. *J Bone Joint Surg (Br).* 1977;59-B (2):173-80.
- [14] Singel TC, Patel MM, Gohil DV. A study of width and height of lumbar pedicles in Saurashtra region. *J Anat Soc India.* 2004;53(1):04-09.
- [15] Tan SH, Teo EC, Chua HC. Quantitative three-dimensional anatomy of cervical, thoracic and lumbar vertebrae of Chinese Singaporean. *Eur Spine J.* 2004;13(2):137-46.
- [16] Lien SB, Liou NH, Wu SS. Analysis of anatomic morphometry of pedicles and safe zone for through-pedicle procedures in the thoracic and lumbar spine. *Eur Spine J.* 2007;16(8):1215-22.
- [17] Patil DK, Bhuyan PS. A morphometric study of the pedicles of dry human typical lumbar vertebrae. *Ind J Basic Appd Med Res.* 2014;3(3):428-33.
- [18] Chandni G, Poonam K, Arvind KP, Antony SD. Morphometrical study of pedicles in lumbar vertebrae and its clinical significance. *J Surg Academia.* 2014;4(1):37-40.
- [19] Marasini RP, Gautam P, Sherchan B, Gurung G, Bacchuram KC. A morphometric study of lumbar spine pedicles in Nepalese population. *J Coll Med Sci-Nepal.* 2014;10(4):12-17.
- [20] Ran B, Li Q, Yu B, Chen X, Guo K. Morphometry of lumbar spinous process via three dimensional CT reconstruction in a Chinese population. *Int J Clin Exp Med.* 2015;8(1):1129-36.

#### PARTICULARS OF CONTRIBUTORS:

1. Associate Professor, Department of Anatomy, IMS and SUM Hospital, Siksha 'O' Anusandhan Deemed to be University, Bhubaneswar, Odisha, India.
2. Professor, Department of Anatomy, IMS and SUM Hospital, Siksha 'O' Anusandhan Deemed to be University, Bhubaneswar, Odisha, India.
3. Professor, Department of Anatomy, IMS and SUM Hospital, Siksha 'O' Anusandhan Deemed to be University, Bhubaneswar, Odisha, India.

#### NAME, ADDRESS, E-MAIL ID OF THE CORRESPONDING AUTHOR:

Dr. Gyanaranjan Nayak,  
Associate Professor, Department of Anatomy, IMS and SUM Hospital, Siksha 'O' Anusandhan Deemed to be University,  
Bhubaneswar, Odisha, India.  
E-mail: drgrn82@gmail.com

Date of Submission: **Dec 06, 2019**

Date of Peer Review: **Jan 10, 2020**

Date of Acceptance: **Feb 07, 2020**

Date of Publishing: **Apr 01, 2020**

**FINANCIAL OR OTHER COMPETING INTERESTS:** None.